

The Impact of Inhalation Delay on Lung Drug Delivery: Using Functional Respiratory Imaging (FRI) to Compare Metered Dose Inhaler (MDI) and MDI + Valved Holding Chamber (VHC) Systems

Am J Respir Crit Care Med 2020;201:A5689 Authors: J. Suggett¹, V. Kushnarev¹, C. Van Holsbeke², S. Van Steen², B. Mignot²; ¹Trudell Medical International, London, ON, Canada, ²Fluida, Antwerp, Belgium.

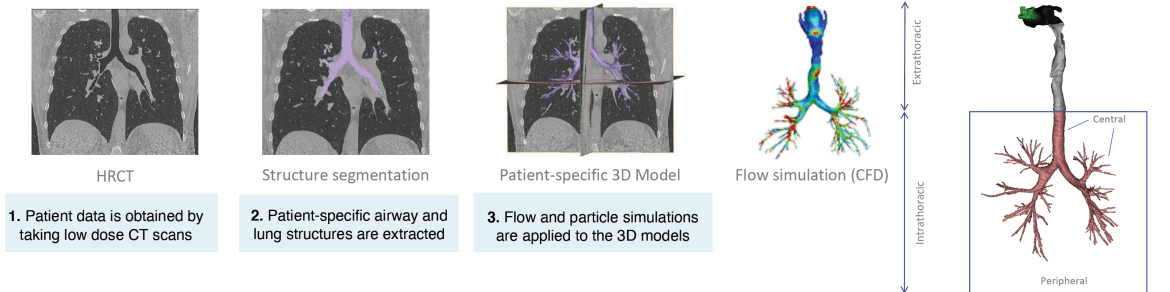
RATIONALE

- Evaluations of inhaler use have demonstrated that mishandling of MDIs is commonplace.
- One of the most common errors is the failure to coordinate inhalation with actuation of the inhaler.
- One of the reasons why VHCs are often prescribed, is to reduce the severity of this error.
- This Functional Respiratory Imaging (FRI) based study assessed the likely severity of a short inhalation delay (from actuation) with an MDI alone and how it contrasted to the use with a VHC.

METHODS

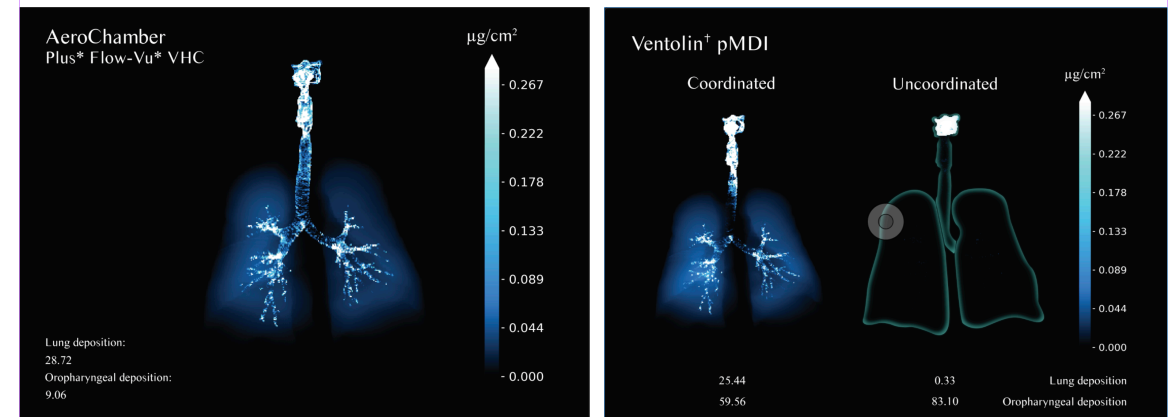
- Three dimensional geometries of airways and lobes were extracted from a CT scan of a 67-year-old male COPD Stage III patient.
- Drug delivery and airway deposition of MDI-delivered albuterol (Ventolin⁺ - HFA, 100mcg) was modelled using FRI with measured particle and plume characteristics with and without an **AeroChamber Plus^{*} Flow-Vu^{*}** VHC.
- For the MDI alone, in addition to the 'perfect' 0-seconds delay, a short inhalation delay of 0.5 seconds was evaluated.
- For the MDI+VHC system, a typical 2 second delay was evaluated.

FUNCTIONAL RESPIRATORY IMAGING



RESULTS

To view the FRI results video, click here: <https://www.trudellmed.com/fri-results-videos>



CONCLUSION

- The FRI deposition profiles highlight the significant negative impact on lung deposition of even a relatively short 0.5 second delay between actuation and inhalation when an MDI is used alone.
- The intrathoracic lung delivery decreased from 25.4mcg to 0.3mcg.
- Extra thoracic delivery (related to oropharyngeal deposition) was consequently even higher.
- The MDI + **AeroChamber Plus^{*} Flow-Vu^{*}** VHC system with a 2 second delay delivered 28.7 mcg to the intrathoracic region with a greater central lung delivery than the MDI alone (perfect coordination) which might be suggestive of greater delivery to beta adrenoreceptors.
- These results further the message that the use of an appropriate VHC should be considered as general practice for all people using MDIs other than those with a highly proficient inhaler technique.